

# Multichannel intraesophageal impedance pattern of children with aerophagia

C. HALB, M. POMERLEAU & C. FAURE

Division of Pediatric Gastroenterology, Department of Pediatrics, CHU Ste-Justine, Montréal, QC, Canada

## Key Messages

- We report a specific MII pattern characterized by excessive air swallows and supragastric belching in children suffering from aerophagia.
- The aim of this study was to determine the multichannel intraesophageal impedance (MII) pattern in children suffering from aerophagia.
- We compared the MII tracings of 5 children with aerophagia according to Rome III criteria to 5 controls.
- The total number of air swallows in patients was significantly higher than in controls but only in the upright position. Supragastric belching was noted only in patients with aerophagia.

## Abstract

**Background** Childhood aerophagia is defined by the Rome III criteria as two or more of the following symptoms; air swallowing, abdominal distension due to intraluminal air, or repetitive belching and/or flatus. The aim of this study was to determine the multichannel intraesophageal impedance (MII) pattern in children suffering from aerophagia. **Methods** We compared the MII tracings of five children with aerophagia according to Rome III criteria (three girls, median age 7 years) to five controls (three girls, median age 8 years). Controls underwent MII for symptoms of gastro-esophageal reflux, and had normal findings. Liquid swallows (LS), air swallows (AS), mixed swallows (MS) and supragastric belching (SGB) were recorded. Meals were excluded from the analysis. All MII parameters were separately analyzed in the upright and recumbent position. All data are reported as median number of events per hour. **Key Results** There was no difference in the total number of LS and MS between the two groups. However, the total

number of AS in patients was significantly higher than in controls (26/h vs 5.5/h,  $p < 0.05$ ) but only in the upright position (46/h vs 8.2 in control group,  $p < 0.05$ ). SGB was noted only in patients with aerophagia (2.6/h vs 0/h,  $p < 0.01$ ). **Conclusions & Inferences** Children suffering from aerophagia have a specific MII pattern with an increased frequency of air swallows in the upright position and supragastric belching. MII may be used as a tool to confirm diagnosis of aerophagia in children.

**Keywords** aerophagia, children, intraesophageal impedance.

## INTRODUCTION

Aerophagia in childhood is defined by the Rome III criteria as two or more of the following signs and symptoms: air swallowing, abdominal distension due to intraluminal air, or repetitive belching or increased flatus occurring for a minimum of 2 months.<sup>1</sup> Presence of an excessive volume of intestinal gas in aerophagia is thought to result from excessive air ingestion. Prevalence has been reported to range between 1.2% (according to Rome II criteria)<sup>2</sup> to 15% in a pediatric population suffering from abdominal pain.<sup>3</sup> A recent pediatric study from Sri Lanka studying aerophagia in a community based population showed a prevalence of 7.5%.<sup>4</sup> Although the proportion of children who seek

## Address for Correspondence

Dr. Christophe Faure, Division of Gastroenterology and Nutrition, Hôpital Sainte-Justine, 3175 Côte Sainte-Catherine, Montréal, Québec, Canada H3T 1C5.

Tel: 514-345-4931 ext. 2561; fax: 514-345-4999;

e-mail: christophe.faure@umontreal.ca

Received: 14 November 2013

Accepted for publication: 4 April 2014

medical attention for aerophagia is unknown, the diagnosis is difficult and is often delayed.<sup>5</sup> Diagnosis of aerophagia is based on the observation of the occurrence of excessive air swallowing or ingestion, which may not be obvious during the consultation at the office. Making the correct diagnosis is of utmost importance as unrecognized aerophagia may lead to unnecessary, invasive, and costly testing and even surgery. Moreover, massive bowel distension, volvulus and intestinal necrosis and perforation have been reported in severe aerophagic children.<sup>6,7</sup>

Multichannel intraesophageal impedance (MII) is able to discriminate between gas, liquid, and mixed swallows, and, therefore episodes of liquid vs air reflux can be quantified.<sup>8</sup> In adults, MII has been validated to objectively measure the occurrence of air swallows and air reflux in aerophagic subjects.<sup>9,10</sup>

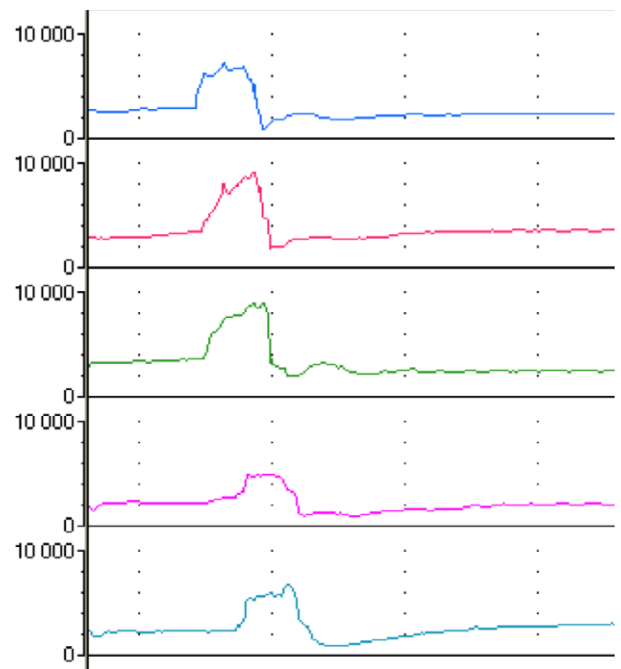
The aim of this study was to test the hypothesis that MII could be used as a tool to help in the diagnosis of aerophagia in children. We report here for the first time a description of MII patterns in children with aerophagia.

## PATIENTS

Ten children were included in this retrospective study: five patients with aerophagia and five controls. Patients with aerophagia fulfilled Rome III criteria for aerophagia.<sup>1</sup> Sex and age-matched controls were selected from the MII database of the Sainte-Justine Motility Centre. Controls underwent testing for symptoms of gastro-esophageal reflux (cough  $n = 3$ ; pain  $n = 2$ ) and had normal findings on MII-pH monitoring (time at pH <4 less than 5%, symptom index <50%, number of reflux episodes <70 episodes in 24 h)<sup>8,11</sup> and result of MII-pH monitoring had no therapeutic consequence.

## METHODS

Ambulatory 24-hour combined esophageal pH and MII recording was performed in all patients. The 24-hour pH-MII was performed using Sleuth recording devices (Sandhill Scientific System, Denver, CO, USA). Positioning of the MII catheter was confirmed by an X-ray. All tracings were manually analyzed using definition of events according to Bredenoord *et al.*<sup>9</sup> A liquid swallow was defined by a drop in impedance greater than 50% from baseline starting at the highest channel and going in the antegrade direction. An air swallow was defined as a peak superior to 1000 ohms above baseline moving in the antegrade direction and measured in the most distal impedance segment (Fig. 1). A mixed swallow was defined as a short peak of more than 1000 ohms above baseline preceding a drop in impedance greater than 50% from baseline moving proximal to distal in the esophagus (Fig. 2). A gastric air reflux or a gastric belch was defined as a rapid rise of more than 3000 Ohms in the retrograde direction over at least two consecutive impedance sites that moved toward the mouth. A supragastric belching was defined as an episode with high impedance (>3000 Ohms), the onset of which started in the proximal channel and moved distally, and the end clearing in the opposite direction (Fig. 3). We also assessed the percentage of time with pH <4. A pathological gastro-esophageal reflux (GER) episode was defined by a total time pH <4 for more than 5% of the study period. Meals were excluded from the analysis for all patients. All



**Figure 1** Air Swallow: A peak of impedance superior to 1000 ohms above baseline moving in the antegrade direction and measured in the most distal impedance segment.

MII parameters were separately analyzed in the upright position and the recumbent position.

Throughout the manuscript, data are reported as the median number of events per hour. The Wilcoxon test was used for comparisons between the two groups. Differences were considered statistically significant when  $p < 0.05$ .

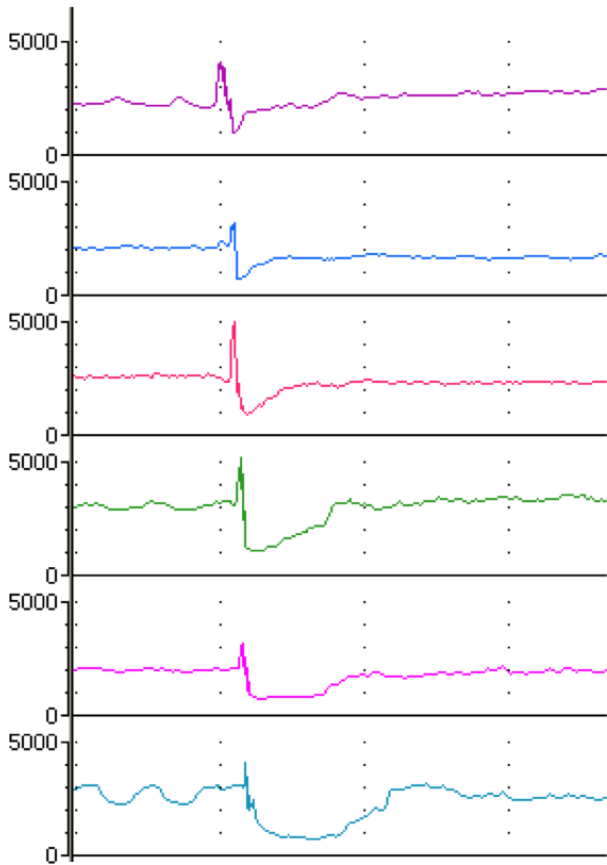
The study was approved by the local Ethics Committee.

## RESULTS

Among the 10 included subjects, there were three girls in each group. The median (range) age of the patients and controls was respectively 7 (range 5–15) and 8 (range 3–15) years ( $p = \text{NS}$ ). Excessive air swallowing was reported in all patients and abdominal distension and abdominal pain. Two of them complained of excessive belching or increased flatus.

Table 1 depicts the MII results of the two groups. The percentage of time with pH <4 was less than 5% in all subjects and was similar for the two groups.

The number of liquid swallows and mixed swallows were similar in the two groups. The total number of air swallows was significantly higher in children with aerophagia compared to controls ( $p < 0.05$ ). Air swallows were significantly more frequent in aerophagic patients in the upright position ( $p < 0.05$ ). Although the total number of gastric belching episodes was higher in aerophagic patients the difference did not



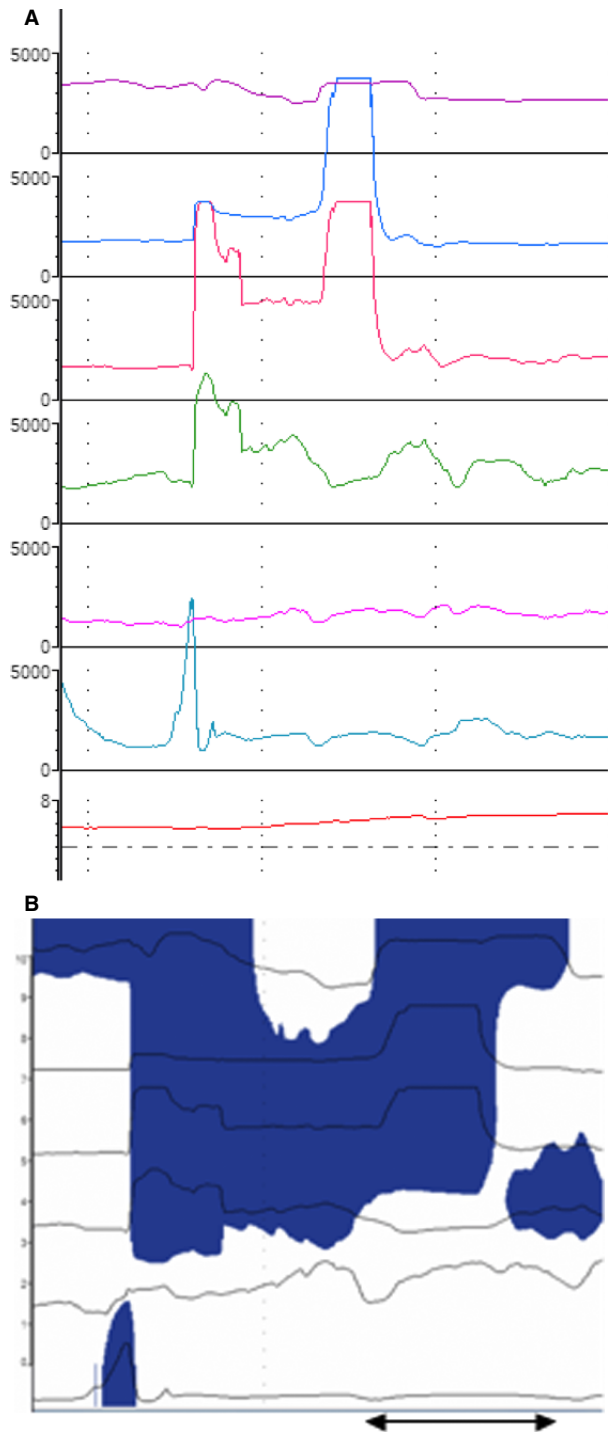
**Figure 2** Mixed Swallow: A short peak of more than 1000 ohms above the baseline preceding a drop in impedance greater than 50% from baseline moving proximal to distal in the esophagus.

reach statistical significance. Supragastric belching was noted only in patients with aerophagia ( $p < 0.01$ ).

**DISCUSSION**

We report in this study the MII pattern of children suffering from aerophagia according to Rome III criteria. Increased number of air swallows in the upright position, and presence of supragastric belching were the main specific features encountered in these children.

Air swallowing during eating and drinking is a normal physiological event.<sup>12</sup> In healthy children, each swallow transports a certain amount of air to the stomach. The stomach protects itself against excessive distension through belching. We demonstrate here that aerophagia in children is the result of repetitive and excessive air swallows while awake and particularly in the upright position. Patients with aerophagia present with supragastric belches more specifically, due to excessive air swallowing, whereas gastric belches were noted in both patients and controls. With supragastric



**Figure 3** (A) Supra gastric belching: An episode with high impedance >3000 Ohms the onset of which starts in the proximal channel and moves distally without reaching the distal impedance channels, clearing in the opposite direction. (B) Same episode wherein the blue color depicts impedance >3000 Ohms showing air ingested into the esophagus and cleared in the aboral direction before it reaches the more distal channel. The black arrow shows the time to expel the air.

**Table 1** Median number (h; range) of events per hour in the 2 groups of subjects

	Patients with aerophagia (n = 5)	Controls (n = 5)	p
Mean recording time	20.2 (19–20.5)	20.5 (15.4–21.5)	NS
Total liquid swallows	9 (7–14)	12 (8–46)	NS
Total mixed swallows	6 (3.5–16)	2 (1–19.5)	NS
Total air swallows	26 (5.9–33)	4.8 (0.5–13)	<0.05
Air swallows in the upright position	46 (10.5–71.6)	8.2 (0.8–22)	<0.05
Air swallows in the recumbent position	4 (1.4–15)	1 (0–3.8)	NS
Total gastric belching	1.3 (0.1–4.6)	0.46 (0–1.8)	NS
Total supragastric belching	2.6 (0.6–12.7)	0	<0.01
Acid liquid reflux	0.4 (0–1.7)	1.4 (0–2)	NS
Non-acid liquid reflux	0.7 (0–0.7)	0.4 (0–1)	NS
Total time pH <4 (%)	1.36 (0–3.8)	1.74 (0–4.6)	NS

NS: Non-significant.

belches, the air does not originate from the stomach but is ingested immediately before it is expelled. This feature is characterized by rapid antegrade and retrograde flow of air in the esophagus that does not reach the stomach.

The present findings are slightly different from previous data reported in adults. A study of MII in subjects with excessive belching compared to healthy adult volunteers identified specific patterns of air transport through the esophagus.<sup>9,10</sup> Supragastric belching has been reported in patients with 'Unspecified Excessive Belching' which definition according to adult Rome III criteria does not require that excessive air swallowing underlies the symptoms.<sup>9</sup> Another study conducted in 10 adults with suspected aerophagia reports a high incidence of air swallow and gastric belching with a low incidence of supragastric belching.<sup>10</sup>

Early recognition and correct diagnosis of aerophagia are important to alleviate the anxiety of both parents and children and to prevent unnecessary testing, treatments, and hospital admissions. In aerophagia, abdominal distension typically increases progressively during the course of the day (minimal in the early morning while reaching a maximum in the late evening) with increased flatus during sleep.<sup>1,13</sup> The demonstration of air swallowing may be tricky during the consultation. By using MII in children with abdominal distension the data reported here may help as a diagnostic tool for aerophagia.

Management of aerophagia depends on the severity of the symptoms.<sup>5</sup> Reassurance, education and dietary modification, such as drinking with a straw and avoidance of chewing gum and gaseous beverages are most often sufficient. An open study recently showed that baclofen may improve symptoms in adults with

supragastric belching.<sup>14</sup> Biofeedback and behavioral therapy have also been proposed as treatments for aerophagia.<sup>15,16</sup> There may be a role for MII in the development of a biofeedback treatment program as supragastric belching is not a reflex, but rather the result of human behavior. Interestingly, because impedance monitoring can differentiate between gastric and supragastric belches, patients can correlate their symptoms with visual input. Hence, MII may help physicians convince their patients that these belches and air swallows are self-induced.

One of the limitations of this study is the small sample size. However, our most interesting finding is that increased frequency of air swallows in the supine position is highly specific for the diagnosis of aerophagia. Supragastric belching was also found specifically in patients with aerophagia. Another limitation of our study is that neurologically impaired children, in whom aerophagia is frequently reported, were not included. However, we believe that the present results may be applied to neurologically impaired children whose gastro-esophageal reflux events have been shown to be detected by MII similar to non-neurologically impaired children.<sup>17</sup> Furthermore, although we were able to recruit pediatric control subjects for obvious ethical reasons they were not asymptomatic healthy controls but can nonetheless be considered as normal controls.

In conclusion, we describe here in children suffering from aerophagia a specific MII pattern characterized by excessive air swallows and supragastric belching. This may help to accurately diagnose aerophagia in children, by providing an objective evaluation in addition to clinical symptoms. MII may give a pathophysiological explanation to children and their parents, making it possible for them to understand the nature and mechanism of their symptoms. This may be helpful to reassure patients, their parents and physicians by confirming the clinical symptom-based diagnosis of aerophagia. Further research is needed to study and prove the diagnostic value of MII in children with aerophagia.

## ACKNOWLEDGMENTS

The authors thank Kelly Grzywacz, MD, for editing the manuscript.

## FUNDING

No funding declared.

## DISCLOSURE

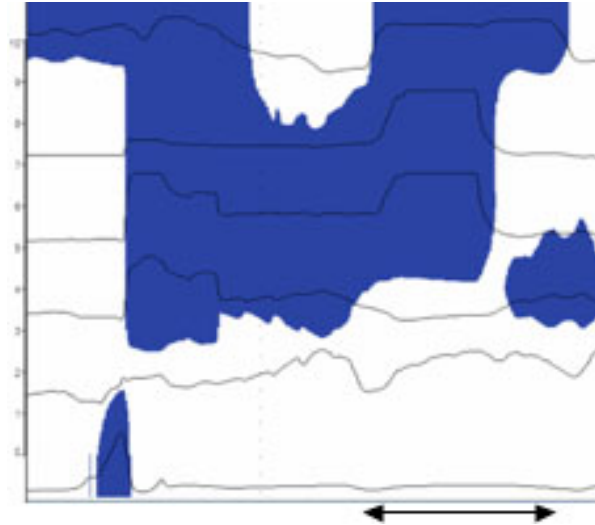None.

## REFERENCES

- 1 Rasquin A, Di Lorenzo C, Forbes D, Guiraldes E, Hyams JS, Staiano A, Walker LS. Childhood functional gastrointestinal disorders: child/adolescent. *Gastroenterology* 2006; **130**: 1527–37.
- 2 Caplan A, Walker L, Rasquin A. Validation of the pediatric Rome II criteria for functional gastrointestinal disorders using the Questionnaire on pediatric gastrointestinal symptoms. *J Pediatr Gastroenterol Nutr* 2005; **41**: 305–16.
- 3 Helgeland H, Flagstad G, GrÅtta J, Vandvik PO, Kristensen H, Markestad T. Diagnosing pediatric functional abdominal pain in children (4–15 years old) according to the Rome III Criteria: results from a Norwegian prospective study. *J Pediatr Gastroenterol Nutr* 2009; **49**: 309–15.
- 4 Devanarayana NM, Rajindrajith S. Aerophagia among Sri Lankan schoolchildren: epidemiological patterns and symptom characteristics. *J Pediatr Gastroenterol Nutr* 2012; **54**: 516–20.
- 5 Chitkara DK, Bredenoord AJ, Wang M, Rucker MJ, Talley NJ. Aerophagia in children: characterization of a functional gastrointestinal disorder. *Neurogastroenterol Motil* 2005; **17**: 518–22.
- 6 Komuro H, Matoba K, Kaneko M. Laparoscopic gastropexy for chronic gastric volvulus complicated by pathologic aerophagia in a boy. *Pediatr Int* 2005; **47**: 701–3.
- 7 Basaran UN, Inan M, Aksu B, Ceylan T. Colon perforation due to pathologic aerophagia in an intellectually disabled child. *J Paediatr Child Health* 2007; **43**: 710–2.
- 8 Mousa HM, Rosen R, Woodley FW, Orsi M, Armas D, Faure C, Fortunato J, O'Connor J *et al.* Esophageal impedance monitoring for gastroesophageal reflux. *J Pediatr Gastroenterol Nutr* 2011; **52**: 129–39.
- 9 Bredenoord AJ, Weusten BL, Sifrim D, Timmer R, Smout AJ. Aerophagia, gastric, and supragastric belching: a study using intraluminal electrical impedance monitoring. *Gut* 2004; **53**: 1561–5.
- 10 Hemmink GJ, Weusten BL, Bredenoord AJ, Timmer R, Smout AJ. Aerophagia: excessive air swallowing demonstrated by esophageal impedance monitoring. *Clin Gastroenterol Hepatol* 2009; **7**: 1127–9.
- 11 Pilic D, Frohlich T, Noh F, Pappas A, Schmidt-Choudhury A, Kohler H, Skopnik H, Wenzl TG. Detection of gastroesophageal reflux in children using combined multichannel intraluminal impedance and pH measurement: data from the German Pediatric Impedance Group. *J Pediatr* 2011; **158**: 650–4 e1.
- 12 Poudroux P, Ergun GA, Lin S, Kahrilas PJ. Esophageal bolus transit imaged by ultrafast computerized tomography. *Gastroenterology* 1996; **110**: 1422–8.
- 13 Hwang JB, Choi WJ, Kim JS, Lee SY, Jung CH, Lee YH, Kam S. Clinical features of pathologic childhood aerophagia: early recognition and essential diagnostic criteria. *J Pediatr Gastroenterol Nutr* 2005; **41**: 612–6.
- 14 Blondeau K, Boeckxstaens V, Rommel N, Farré R, Depeyter S, Holvoet L, Boeckxstaens G, Tack JF. Baclofen improves symptoms and reduces postprandial flow events in patients with rumination and supragastric belching. *Clin Gastroenterol Hepatol* 2012; **10**: 379–84.
- 15 Kessing BF, Bredenoord AJ, Smout AJ. Mechanisms of gastric and supragastric belching: a study using concurrent high-resolution manometry and impedance monitoring. *Neurogastroenterol Motil* 2012; **24**: e573–9.
- 16 Koslowe O, Chitkara DK. Aerophagia. In: Faure C, Di Lorenzo C, Thapar N, eds. *Pediatric Neurogastroenterology*. New York, NY: Springer, 2013: 401–4.
- 17 Del Buono R, Wenzl TG, Rawat D, Thomson M. Acid and nonacid gastro-oesophageal reflux in neurologically impaired children: investigation with the multiple intraluminal impedance procedure. *J Pediatr Gastroenterol Nutr* 2006; **43**: 331–5.

## Graphical Abstract

The contents of this page will be used as part of the graphical abstract of html only. It will not be published as part of main.



Supragastric belching: An episode with high impedance wherein the blue color depicts impedance  $>3000$  Ohms, the onset of which starts in the proximal channel and moves distally without reaching the distal impedance channels, clearing in the opposite direction.