

Esophageal Dysmotility Is Present Before Surgery in Isolated Tracheoesophageal Fistula

*Caroline Lemoine, *Ann Aspirot, *Melanie Morris, and †Christophe Faure

ABSTRACT

After surgical correction of esophageal atresia with or without tracheoesophageal fistula, esophageal body motility dysfunction has been reported in nearly all patients. Using high-resolution esophageal manometry before surgical repair in 2 children with isolated tracheoesophageal fistula, we sought to determine whether dysmotility was present before any surgical insult to test the hypothesis that dysmotility associated with esophageal atresia with or without tracheoesophageal fistula is related to intrinsic primary factors linked to abnormal development of the esophagus. Both had an abnormal esophageal motility: one exhibited hypomotility with distal contraction, whereas the other showed a complete aperistalsis pattern. This suggests that esophageal dysmotility is congenital in nature rather than secondary to surgery.

Key Words: esophageal atresia, esophageal dysmotility, H-type tracheoesophageal fistula, high-resolution esophageal manometry, isolated tracheoesophageal fistula

(*JPGN* 2015;60: 642–644)

Esophageal atresia with or without tracheoesophageal fistula (EA-TEF) is the most common congenital esophageal malformation. According to Gross classification, 6 different EA-TEF subtypes have been described (1). The presence of an isolated TEF without discontinuity of the esophagus constitutes the fifth type of EA-TEF (isolated TEF or H-type) and comprises approximately 4% of esophageal atresia and related anomalies (1).

After surgical correction of EA-TEF, esophageal body motility dysfunction has been reported in nearly all of the patients leading to complications such as gastroesophageal reflux, esophagitis, and dysphagia (2,3). The underlying cause of this dysmotility remains unclear and controversial. In patients with EA-TEF who have undergone surgery, it has been postulated that it may be caused either by intrinsic factors related to abnormal development of the esophagus or by maneuvers responsible for a partial denervation. Postoperative complications (including leaks, stenosis, and subsequent esophageal pneumatic dilations) could also cause local trauma and inflammation leading to further neuronal and muscular damage. In patients with isolated TEF, the surgery that merely consists of ligation of the fistula through a cervical incision with no

anastomosis is less aggressive than EA-TEF repair and should therefore produce less injury and damage to the esophagus. Despite an apparently less severe malformation, patient symptomatology is, however, similar to that of patients with EA, with a late occurrence of dysphagia and gastroesophageal reflux affecting almost half of the patients, suggesting that esophageal dysmotility could also be severely impaired (4).

Using high-resolution esophageal manometry (HREM) before surgical repair in 2 children with isolated TEF, we sought to determine whether dysmotility was present before any surgical insult to test the hypothesis that dysmotility associated with EA-TEF is related to intrinsic primary factors linked to abnormal development of the esophagus.

METHODS

Patients

Two girls with isolated TEF were investigated preoperatively using HREM performed as an outpatient procedure. In both patients, esophageal manometry was part of the diagnostic workup. Information was gathered from the medical charts: demographic, medical history, symptomatology before HREM.

HREM Technique

HREM was performed in an outpatient setting after a 4-hour fast. The procedure was conducted without sedation, with the child placed in supine position. The catheter (outside diameter of 4.2 mm; Sierra Scientific Instruments, Los Angeles, CA) was inserted transnasally until the most distal recording site was positioned in the stomach. Time was allowed for the patient to calm down with

TABLE 1. HREM derived variables

Manometry-related data	Patient 1	Patient 2
UES		
Median basal pressure, mmHg	76	114
Median residual pressure, mmHg	17.8	14.0
LES		
Median basal pressure (13–43 mmHg), mmHg	33	16.5
IRP 4 s (<15 mmHg)	8.9	3.5
Esophageal body		
Median DCI (500–3600 mmHg · cm · s)	138.2	—
Median DCIa (22.6–139.2 mmHg · s)	9.9	—
Median PFV (2.6–5.3 cm/s)	17.2	—
Median TZ, cm	6.4	—

Normal values refer to Goldani et al (6) (unavailable for UES). DCI = distal contractile integral; DCIa = distal contractile integral adjusted; HREM = high-resolution esophageal manometry; IRP = integrated relaxation pressure; LES = lower esophageal sphincter; PFV = pressurization front velocity; TZ = transition zone; UES = upper esophageal sphincter.

Received April 4, 2014; accepted December 4, 2014.

From the *Division of Pediatric Surgery, and the †Division of Gastroenterology, Hepatology, and Nutrition, Centre Hospitalier Universitaire Sainte-Justine, Université de Montréal, Montréal, Québec, Canada.

Correspondence to Christophe Faure, MD, Division of Gastroenterology and Nutrition, Hôpital Sainte-Justine, 3175 Côte Sainte-Catherine, Montréal, Québec, Canada, H3T 1C5 (e-mail: christophe.faure@umontreal.ca).

The authors report no conflicts of interest.

Copyright © 2015 by European Society for Pediatric Gastroenterology, Hepatology, and Nutrition and North American Society for Pediatric Gastroenterology, Hepatology, and Nutrition

DOI: 10.1097/MPG.0000000000000667

the catheter in place. Once the tracing stabilized, stomach, diaphragm, lower esophageal sphincter (LES), and upper esophageal sphincter positions were determined. Water boluses (5.0 mL) were administered by syringe every 30 seconds. Ten wet swallows were obtained for each patient.

HREM Analysis

Data were derived using the Manoview analysis software version 2.0.1 (Sierra Scientific Instruments). All of the tracings were reviewed and analyzed by a general surgery resident (C.L.) under the supervision of a pediatric gastroenterologist (C.F.) and

a pediatric surgeon (A.A.). Swallowing was determined by pharyngeal contraction, followed by the upper esophageal sphincter relaxation. LES tone and relaxation were then evaluated; mean residual pressure and 4 seconds integrated relaxation pressure of the LES following swallowing and basal pressure were also measured. Esophageal length corresponded to the distance between both esophageal sphincters. The dominant characteristics of the esophageal contraction after swallows were described after generating isobaric contour plots at a 30-mmHg threshold pressure. Patients were classified according to their main peristaltic propagation pattern according to previously published classifications (5,6). In the patient showing evidence of peristaltic propagation, even if weak or abnormal, the following characterization was conducted:

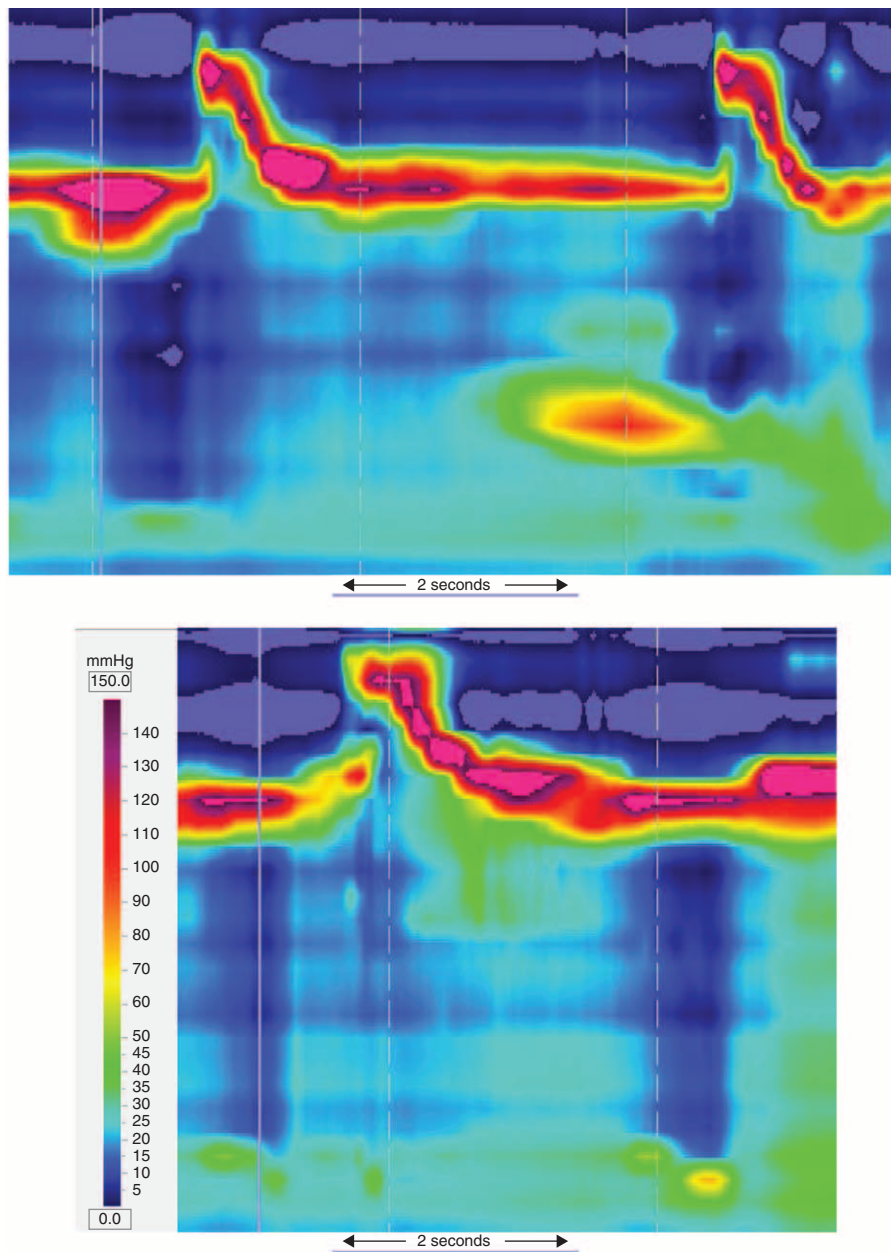


FIGURE 1. Peristalsis pattern identified at HREM evaluation. Top panel: Patient 1 with distal contractions; Bottom panel: Patient 2 with aperistalsis. HREM=high-resolution esophageal manometry.

proximal and distal troughs were identified. Using isobaric contour line at 30 mmHg, the transition zone was measured; the distal contractile integral (DCI) and contraction front velocity were both determined using the Manoview analysis software. DCI was then adjusted for esophageal length (DCIa). These data were compared with the only available pediatric reference HREM values obtained in 15 children tested for dysphagia with normal peristaltic pattern (6).

RESULTS

One patient was evaluated because of a history of repeated pulmonary infections whereas the other was evaluated for abdominal distension and dysphagia. TEF was demonstrated on esophagogram. Both patients underwent an upper gastrointestinal endoscopy before their manometric evaluation. In both cases, the fistula was identified and no esophagitis was present. Manometry was performed at age 3.7 and 3.8 years before surgical repair.

HREM demonstrated abnormal esophageal motility in the 2 patients. Both patients were classified as having an aperistaltic pattern because of an absence of continuous isobaric contour at the 30 mmHg threshold pressure. One patient, however, exhibited evidence of distal contraction. The second patient had a complete lack of esophageal motility, representing a complete esophageal aperistalsis. LESs were normal (Table 1). HREM esophageal motility patterns are presented in Figure 1.

DISCUSSION

The present study shows that esophageal motility is severely impaired in children with isolated TEF before any surgery, suggesting that the dysmotility is related rather to abnormal development of the innervation and smooth muscle of the esophagus than to surgical maneuvers.

Esophageal dysmotility affects nearly all operated patients with EA-TEF and constitutes one of the main issues in the long-term follow-up of these patients (2,3). The origin of this dysmotility remains unknown. Mechanical causes linked to surgery and post-operative complications are believed to be an important cause, but some studies suggest the presence of an underlying congenital neuronal or muscular defect (7–10).

Two motor patterns were seen in the patients, one with complete aperistalsis and the other with evidence of distal contraction. These motility patterns were the same as those reported in EA-operated patients despite a near-to-normal grossly foregut development. Abnormally low DCI and DCIa values probably represent abnormal underlying esophageal innervation and/or smooth musculature.

In patients with EA-TEF, the key role of the abnormal development of esophageal innervation and musculature in esophageal dysmotility is supported by several lines of evidence. Romeo et al (11) have reported an esophageal manometry study in 20 newborns with EA and have demonstrated motor abnormalities in the proximal (pouch) and distal esophagus before surgery. Similarly, abnormal esophageal motility patterns with aperistalsis have been described in adults with isolated TEF without atresia before surgical repair (12,13). Pathological data also support the role of abnormal intrinsic and vagal innervation of the esophagus. Detailed analysis of esophageal intrinsic innervation in deceased EA newborns reported abnormalities in the Auerbach plexus (9). Other studies found hypoplasia of esophageal innervation or smooth muscle (8) in the upper pouch (10) or in the fistula (7,8). Findings on adriamycin-induced EA-TEF fetal rat model have similarly shown an abnormal distribution of nerve tissue in the esophagus (14) and inherent abnormalities in the branching pattern of the vagus nerves (15).

Although this is the first study to report detailed data on esophageal motility assessed by HREM in isolated TEF children before surgical repair, we are aware that only 2 patients were included. Because the esophageal motility was found deeply disorganized in these young patients who had no other reasons (no esophagitis, no congenital stenosis, no abnormal LES relaxation, and no surgical insult) to explain the dysmotility, we believe that these findings provide important elements in the pathophysiology of EA-TEF-associated esophageal motor disorders.

We conclude that, despite an apparently less severe esophageal malformation, patients with isolated TEF present with impaired esophageal motility before any surgical procedure. This finding suggests that the esophageal dysmotility known to affect patients with EA and TEF is probably primary in origin rather than secondary to mechanical surgical trauma.

Acknowledgments: We thank Lyse Giguère, RN, for excellent technical assistance.

REFERENCES

- Gross R. *Surgery of Infancy and Childhood*. Philadelphia: WB Saunders; 1953.
- Lemoine C, Aspirot A, Le Henaff G, et al. Characterization of esophageal motility following esophageal atresia repair using high-resolution esophageal manometry. *J Pediatr Gastroenterol Nutr* 2013;56:609–14.
- Sistonen SJ, Koivusalo A, Nieminen U, et al. Esophageal morbidity and function in adults with repaired esophageal atresia with tracheoesophageal fistula: a population-based long-term follow-up. *Ann Surg* 2010; 251:1167–73.
- Crabbe DC, Kiely EM, Drake DP, et al. Management of the isolated congenital tracheo-oesophageal fistula. *Eur J Pediatr Surg* 1996;6:67–9.
- Pandolfino JE, Ghosh SK, Rice J, et al. Classifying esophageal motility by pressure topography characteristics: a study of 400 patients and 75 controls. *Am J Gastroenterol* 2008;103:27–37.
- Goldani HA, Staiano A, Borrelli O, et al. Pediatric esophageal high-resolution manometry: utility of a standardized protocol and size-adjusted pressure topography parameters. *Am J Gastroenterol* 2009; 105:460–7.
- Li K, Zheng S, Xiao X, et al. The structural characteristics and expression of neuropeptides in the esophagus of patients with congenital esophageal atresia and tracheoesophageal fistula. *J Pediatr Surg* 2007; 42:1433–8.
- Dutta HK, Mathur M, Bhatnagar V. A histopathological study of esophageal atresia and tracheoesophageal fistula. *J Pediatr Surg* 2000;35: 438–41.
- Nakazato Y, Wells TR, Landing BH. Abnormal tracheal innervation in patients with esophageal atresia and tracheoesophageal fistula: study of the intrinsic tracheal nerve plexuses by a microdissection technique. *J Pediatr Surg* 1986;21:838–44.
- Boleken M, Demirbilek S, Kirimiloglu H, et al. Reduced neuronal innervation in the distal end of the proximal esophageal atretic segment in cases of esophageal atresia with distal tracheoesophageal fistula. *World J Surg* 2007;31:1512–7.
- Romeo G, Zuccarello B, Proietto F, et al. Disorders of the esophageal motor activity in atresia of the esophagus. *J Pediatr Surg* 1987;22:120–4.
- Gundry SR, Orringer MB. Esophageal motor dysfunction in an adult with a congenital tracheoesophageal fistula. *Arch Surg* 1985;120:1082–3.
- Heitmiller RF, Nikoomanesh P, Ravich WJ. Esophageal motility in an adult with a congenital H-type tracheoesophageal fistula. *Dysphagia* 1990;5:138–41.
- Qi BQ, Uemura S, Farmer P, et al. Intrinsic innervation of the oesophagus in fetal rats with oesophageal atresia. *Pediatr Surg Int* 1999;15:2–7.
- Qi BQ, Meri J, Farmer P, et al. The vagus and recurrent laryngeal nerves in the rodent experimental model of esophageal atresia. *J Pediatr Surg* 1997;32:1580–6.